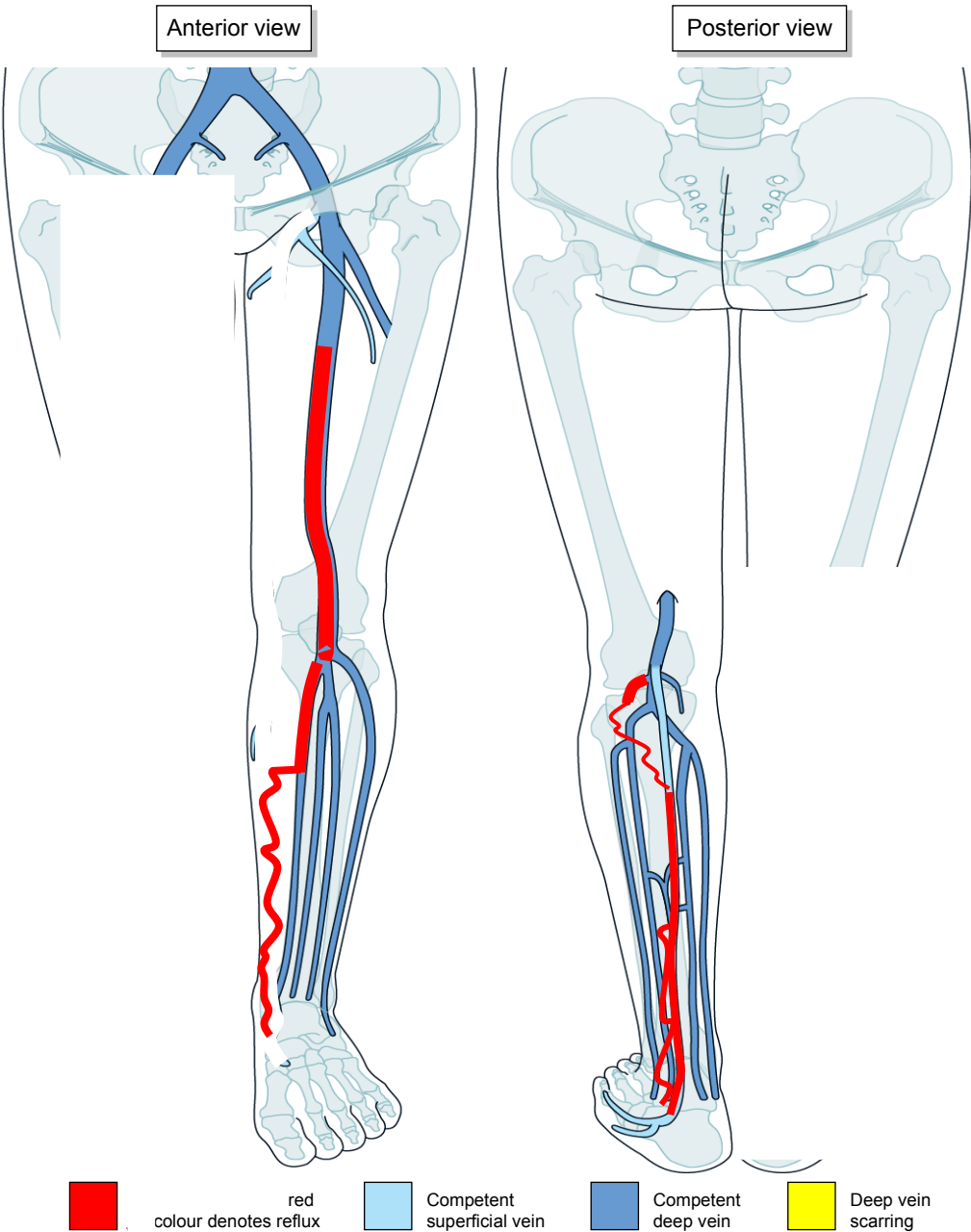


Vascular lab report

Assessed by: Suleman Choudhury



US Doppler lower limb veins Lt:

The Sapheno-Femoral Junction (SFJ) was not visualised and the Greater Saphenous vein (GSV) appeared to be absent – patient has had a previous venous procedure.

The Sapheno-Popliteal Junction (SPJ) and proximal Short Saphenous vein (SSV) are patent and competent.

Incompetent gastrocnemius vein perforators reflux into the mid-SSV causing incompetence and filling small varices in the posterior aspect of the calf.

The mid-distal Femoral, Popliteal, Gastrocnemius and proximal Posterior Tibial veins are patent and incompetent. The Posterior Tibial vein refluxes into an incompetent perforator and fills varices (5.0mm) in the medial aspect of the calf. These varices course to the foot.

All other deep veins are all patent and competent.
